

Advanced Dental Laser Surgery

authors_ Dr. Rudolf Walker, Dr. Gerd Volland, Germany

The laser application in dental surgery has become a standard tool for many dental clinics around the world. The instrumentation became less costly and more advanced. The use of a diode laser demonstrates many advantages compared to the scalpel, but as in life one has to deal with some disadvantages also. One of the main hurdles has been the price and the teaching about laser applications in dentistry.

The main advantages for the laser are the cutting effect on tissue at the same time tissue is removed and bleeding is almost stopped. By using the laser beam in the bare fiber mode one of the disadvantages is the temperature rise at the edges of the wound. Due to this effect the wound healing is prolonged in comparison to the standard scalpel cut. Those edges do show a carbonization zone, which is responsible for the prolonged healing time.

However to achieve proper cutting the surgeon has to apply enough laser energy to cut and vaporize tissue. To overcome the prolonged healing the stitches have to be in the wound longer than it would be compared to the standard scalpel cuts.

With the electro cauter the edges of the wound are even more coagulated than with the laser beam. The wound healing does show the same effect like the laser cuts. The patient has the advantages of the laser cut, however has to accept the longer wound healing.

To avoid all those disadvantages we have developed a scalpel which carries the laser energy from the diode laser to the sharp edges of this knife.

This sapphire knife was developed in cooperation with surgeons working daily with this new technology now.

As a producer of the FOX diode laser we have developed this knife to overcome the problems of the free beam laser and also the problem of cutting with the scalpel alone. (Fig. 1) The revolution is the coagulating, cutting knife. The scalpel can be used as a standard surgical knife with all the advantages of the tactile feedback, but at the same time having the laser to coagulate at the sharp edges. The laser light exits the knife at the edges where it cuts. (Fig. 2)



Fig. 1

The temperatures achieved with the sapphire knife are in the range of $> 65^{\circ}$ to allow coagulation, but less than 100° to avoid carbonization. The cut is only performed by the knife itself. To allow the laser to exit at the right edges a mathematical calculation has been performed for maximum transmission and reflection inside the knife. Thus the absorption inside the knife is minimal and no temperature rise at the handle is produced. The result is a cut which is almost free of bleeding and no cleaning of the wound is required during surgery. Higher visibility at the cuts and faster healing compared to the laser cuts are the results of this exciting invention. (Abb. 3 to 6)

Using this knife during the last month we have demonstrated the superiority of this technique. The very first tests have been performed using a pork liver to research the cuts and look at the histology of the



Fig. 2

Fig. 1_ Fox with sapphire knife (Jazz)

Fig. 2_ Sapphire knife (side view).

For the necrosis zone please look Fig. 7)

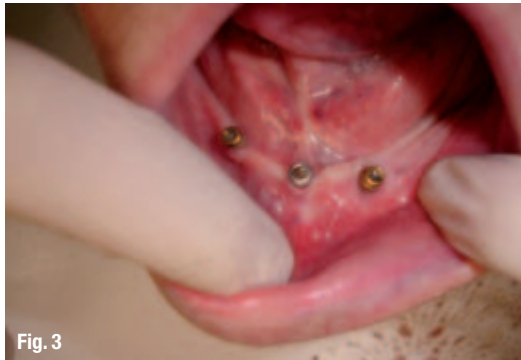

Fig. 3

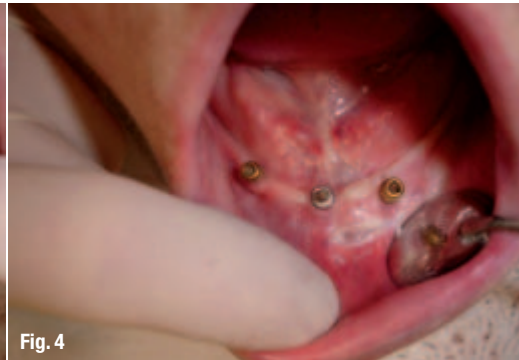

Fig. 4

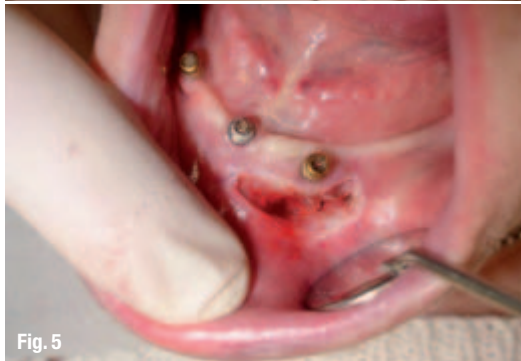

Fig. 5

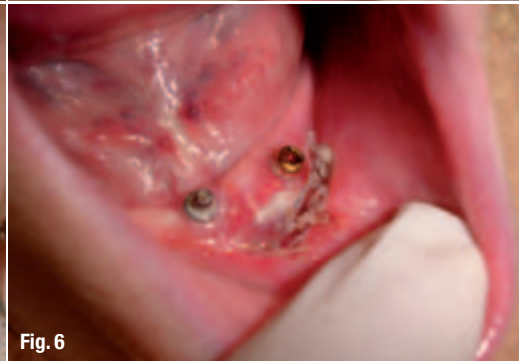

Fig. 6

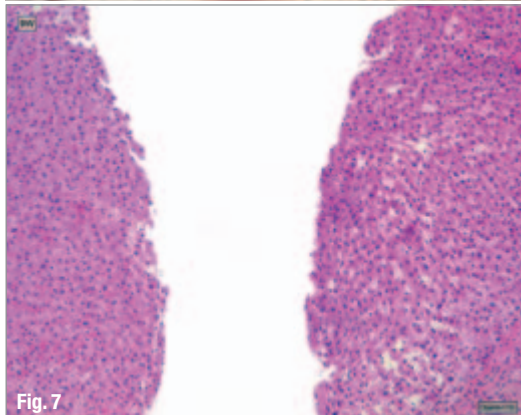


Fig. 7

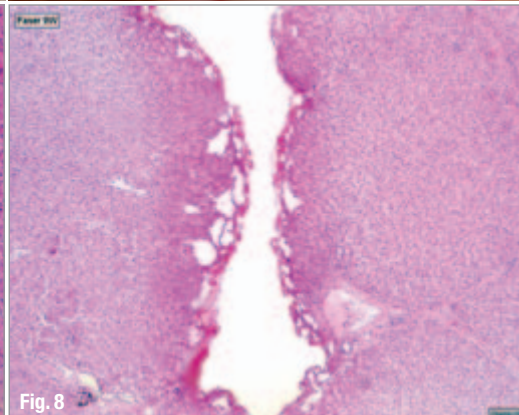


Fig. 8

Fig. 3-6 Patient 75 years lower jaw Implants with recurring inflammation at the implant (regio 33).

Fig. 3 Initial situation Missing attached gingival at implant regio 33.

Fig. 4 Vestibulum plastic cuts with lateral denaturation.

Fig. 5 Deep cut: muscle cut in two and inlaying strands pre suturing.

Fig. 6 First day post OP. Prosthesis was immediately prolonged at the edge. Fibrin eschar. Patient without pain and complains.

Fig. 7 Cut in a liver using the Jazz.

Fig. 8 Reference cut with a free laser beam into a liver.

wound edges. The histology has proven that the edges do not show any major necrosis zones. The cuts are clean with minimal demonstrations of heat being applied.

To compare those cuts with the standard free beam laser cuts, one can immediately see the difference. The large necrosis zones with the laser are highly visible and therefore lead to the prolonged healing time, whereas the cuts with our new JAZZ are clean and almost comparable to the standard scalpel cuts. (Figs. 7 and 8)

_contact	laser
<p>Dr Rudolf Walker A.R.C.Laser GmbH Bessemerstr.14 90411 Nürnberg, Germany Tel.: +49/9 11/2 17 79-0 Fax: +49/9 11/2 17 79-99 E-mail: info@arclaser.de</p>	